

Evaluation of Elastic Stiffness and Tendon Thickness in the Quadriceps Tendon in Patients Undergoing Chronic Hemodialysis

Kronik Hemodiyaliz Hastalarında Kuadriseps Tendonunda Elastik Sertlik ve Tendon Kalınlığının Değerlendirilmesi

Elçin Aydın¹, Sedit Kıvanç Muratlı², Ayşe Gül Temizkan Kırkayak³, Mustafa Agah Tekindal⁴,
Muhteşem Ağıldere⁵

¹University of Health Sciences Turkey, İzmir Bayraklı City Hospital, Department of Radiology, İzmir, Turkey

²Çanakkale Onsekiz Mart University Hospital, Department of Ortopedics, Çanakkale, Turkey

³Buca Seyfi Demirsoy Training and Research Hospital, Clinic of Nephrology, İzmir, Turkey

⁴İzmir Katip Çelebi Hospital, Clinic of Biostatistics, İzmir, Turkey

⁵Başkent University Faculty of Medicine, Department of Radiology, Ankara, Turkey

Cite as: Aydın E, Muratlı SK, Temizkan Kırkayak AG, Tekindal MA, Ağıldere M. Evaluation of Elastic Stiffness and Tendon Thickness in the Quadriceps Tendon in Patients Undergoing Chronic Hemodialysis. Anatol J Gen Med Res. 2024;34(2):171-6

Abstract

Objective: Spontaneous rupture of the quadriceps tendon is more common in patients with chronic renal failure than in the healthy population. Recurrent microtrauma, hypoxia, hyperparathyroidism, and chronic acidosis are some predisposing factors for spontaneous rupture. This study aimed to evaluate tendon thickness and sonoelastography findings of the quadriceps tendon in patients with chronic renal failure undergoing a dialysis program.

Methods: Forty randomly allocated patients [24 male, 16 female; mean (\pm standard deviation (SD)) age: 58.18 \pm 14.41 years [range: 24-75] with chronic renal failure undergoing dialysis program, and 32 healthy volunteers 10 males, 22 females; mean age (\pm SD): 54.72 \pm 13.84 (range: 31-74)] were included. Measurements of quadriceps tendon thickness and strain elastography were performed in the right knees of all subjects. For the measurement of a strain ratio, two ROIs were placed on the tendon that was 1 cm proximal to the patellar insertion area (ROI A) and the prefemoral fat area (ROI B).

Results: The mean quadriceps tendon thickness values were 6.55 \pm 1.77 mm (range: 3.8-9.4 mm) in the chronic renal failure group and 5.81 \pm 0.93 mm (range: 4.3-8.3 mm) in the control group. The quadriceps tendons were significantly thicker in the patient group ($p=0.03$). The mean elasticity scores were 6.88 \pm 15.82 in patients with chronic renal failure group and 8.49 \pm 15.07 in the control group. Mean strain elastography values showed no statistically significant difference ($p=0.66$).

Conclusion: Compared with the control cases, the increase in the thickness of quadriceps tendons was found to be significant, but there was no significant difference in sonoelastography findings between the two groups.

Keywords: Chronic renal failure, hemodialysis, musculoskeletal ultrasound, quadriceps tendon, sonoelastography



Address for Correspondence/Yazışma Adresi: Assoc. Prof. Elçin Aydın, University of Health Sciences Turkey, İzmir Bayraklı City Hospital, Department of Radiology, İzmir, Turkey
Phone: +90 532 641 91 64 **E-mail:** elcinaydin09@yahoo.com.tr
ORCID ID: orcid.org/0000-0003-0907-3647

Received/Geliş tarihi: 08.03.2022
Accepted/Kabul tarihi: 05.01.2024



Copyright© 2024 The Author. Published by Galenos Publishing House on behalf of University of Health Sciences Turkey, İzmir Tepecik Education and Research Hospital. This is an open access article under the Creative Commons AttributionNonCommercial 4.0 International (CC BY-NC 4.0) License.

Öz

Amaç: Kuadriseps tendonunun spontan rüptürü, kronik böbrek yetmezliği olan hastalarda sağlıklı popülasyona göre daha yaygındır. Tekrarlayan mikrotravmalar, hipoksi, hiperparatiroidizm ve kronik asidoz spontan rüptür için predispozan faktörlerden bazılarıdır. Bu çalışmanın amacı kronik böbrek yetmezliği nedeniyle diyaliz programına alınmış olan hastalarda kuadriseps tendonunun kalınlığını ve sonoelastografik bulgularını değerlendirmektir.

Yöntem: Diyaliz programına giren kronik böbrek yetmezliği olan rastgele seçilmiş 40 hasta [24 erkek, 16 kadın; ort [\pm standart sapma (SS)] yaş: 58,18 \pm 14,41 yıl (dağılım: 24-75)] ve 32 sağlıklı gönüllü [10 erkek, 22 kadın; ort (\pm SS) yaş: 54,72 \pm 13,84 (dağılım: 31-74)] çalışmaya dahil edildi. Kuadriseps tendon kalınlığı ve gerinim elastografisi ölçümleri tüm deneklerin sağ dizlerinde gerçekleştirilmiştir. Gerinim oranının ölçümü için, patellar insersiyon alanının 1 cm proksimalindeki tendon üzerine (ROI A) ve prefemoral yağ alanına (ROI B) iki ROI yerleştirildi.

Bulgular: Ortalama kuadriseps tendon kalınlığı değerleri kronik böbrek yetmezliği olan hasta grubunda 6,55 \pm 1,77 mm (dağılım: 3,8-9,4 mm) ve kontrol grubunda 5,81 \pm 0,93 mm (dağılım: 4,3-8,3 mm) idi. Kuadriseps tendonları hasta grubunda anlamlı olarak daha kalındı ($p=0,03$). Ortalama elastisite skorları kronik böbrek yetmezliği olan hasta grubunda 6,88 \pm 15,82 iken kontrol grubunda 8,49 \pm 15,07 idi. Ortalama strain elastografi değerleri istatistiksel olarak anlamlı farklılık göstermedi ($p=0,66$).

Sonuç: Kontrol grubu ile karşılaştırıldığında kuadriseps tendon kalınlığındaki artış istatistiksel olarak anlamlı derecede yüksek olamakta birlikte, sonoelastografik bulgularda iki grup arasında anlamlı bir fark saptanmamıştır.

Anahtar Kelimeler: Kronik böbrek yetmezliği, hemodiyaliz, kas-iskelet sistemi ultrasonu, kuadriseps tendonu, sonoelastografi

Introduction

Quadriceps tendon rupture is a relatively uncommon injury predominantly affecting middle-aged males⁽¹⁾. Disruption of the knee extensor mechanism is a significant disabling injury mostly requiring surgical reconstruction and should thus be diagnosed early. Although spontaneous rupture of the quadriceps tendon tends to occur in older patients with degenerative changes, systemic/metabolic diseases like chronic renal failure also have harmful effects on the tendons. Metabolic acidosis and hyperparathyroidism in patients with chronic renal failure receiving hemodialysis may cause impairment of vascular supply and alter the microstructural properties of the tendon, resulting in spontaneous rupture of the tendon⁽¹⁻⁶⁾.

Although most quadriceps tendon ruptures can be easily diagnosed by history and physical assessment, imaging studies are required for the confirmation of the diagnosis and for differentiating complete and incomplete ruptures^(1,7). Imaging studies of suspected quadriceps tendon ruptures should begin with orthogonal plain radiographs. Several diagnostic imaging modalities may be used in addition to standard radiographs to confirm the diagnosis, such as ultrasound and magnetic resonance imaging (MRI). Arthrography was widely used before, but the availability of MRI has reduced its importance. Ultrasonography (US) is a safe method that allows real-time and non-invasive imaging without exposure to ionizing radiation in a short examination time. It also allows comparative examination in the same session and is relatively inexpensive^(8,9). Although

its reliability is highly dependent on the experience of the operating radiologist, the advantages of US make it the first imaging method to be chosen after physical examination and plain radiographs^(8,9).

Sonoelastography (SE) is an assistive ultrasound technology that enhances the characterization of the lesion by assessing the elasticity of soft tissues. With this method, calculated strain values help effective evaluation of stiffness characteristics of tissues and organs, similar to a more advanced form of palpation with objective data. SE was previously used to evaluate the strain characteristics of superficial soft tissues such as the breast, thyroid gland, lymph nodes, and muscle tissue. Currently, strain analysis of visceral organs has also become applicable^(10,11). There are recent studies concerning the use of SE in musculoskeletal pathologies^(12,13). In particular, in comparative studies with MRI, the reliability of the assessment of the tendinopathy area by SE has been demonstrated⁽¹³⁾. In addition, SE is a useful method in cases where it is difficult to identify tendinopathy by conventional US⁽¹²⁾.

Although the number of studies concerning the elastographic evaluation of tendon disorders has increased in recent years, studies assessing the elastographic characteristics of the quadriceps tendon in patients with chronic renal failure are very limited⁽²⁾. The objective of this study was to analyze the diagnostic efficacy of SE in tendinous injuries by evaluating the elastographic characteristics of the quadriceps tendon using SE in patients with chronic renal failure undergoing a hemodialysis program.

Materials and Methods

Subjects

Our study group included 40 patients (24 males, 16 females; mean age: 58.18 ± 14.41 , range: 24-75 years) who were undergoing hemodialysis (three times a week) with a diagnosis of chronic renal failure at our institution from May 2018 to June 2019. The control group consisted of 32 healthy individuals (10 males, 22 females; mean age: 54.72 ± 13.84 , range: 31-74 years). Measurements were performed on the right knees of all subjects. The age, gender, body height, and weight of all subjects were recorded. Patients with a history of knee surgery, tendon rupture, other systemic and/or inflammatory diseases, and systemic and/or intraarticular use of corticosteroids were excluded. All measurements were performed by the same blinded radiologist (experienced 4 years in real-time SE) who did not know the clinical preliminary diagnosis. A written informed consent form was obtained from all patients. This study was approved by the Clinical Research Ethical Committee of Başkent University (ref no: KA-19/21).

US and Real-time SE

US and real-time SE were performed using a linear-array 13.5-MHz high-resolution transducer (Hitachi Arietta V70, Japan). The examinations were performed in the supine position with the hips and knees in 45° flexion and the feet on the examination table. Initially, all patients underwent standard ultrasound examination. Tendon thickness and elastographic measurements were performed 1 cm proximal to the patellar insertion of the quadriceps tendon. Tendon thickness values were recorded by measuring the

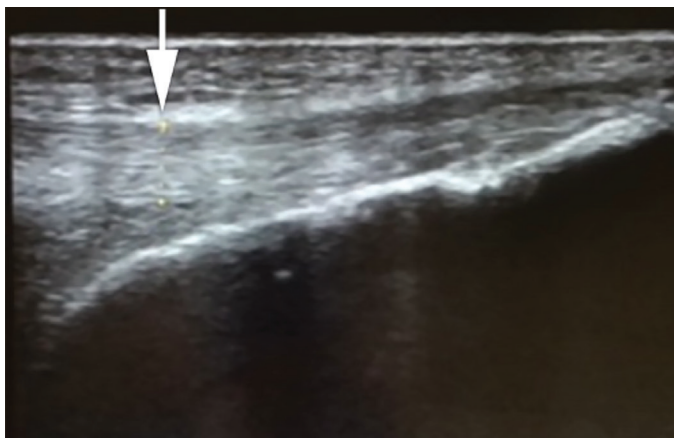


Figure 1. Measurement of quadriceps tendon thickness in Sagittal B-mode display

anteroposterior diameters along the longitudinal axis (Figure 1).

SE images were obtained by applying repeated compression loads to the quadriceps tendon area with the probe. A real-time image was displayed on the original gray-scale ultrasound image, and the sonoelastogram was displayed in overlay mode within the selected ROIs as a color and numerically coded real-time image. The color scale ranged from red for tissues with the greatest strain (softest areas) to blue for tissues with no strain (hardest areas). The relative stiffness of the tissues was represented by the ROI ratios on the sonoelastogram. To measure the strain ratio, two ROIs were placed on the tendon 1 cm proximal from the patellar insertion area (ROI A) and the prefemoral fat pad area (ROI B). The strain ratios (B/A) were calculated by the elastography software of the US device using these two areas (B/A) (Figure 2). ROI areas were used in standard sizes in all measurements. Patients' identities were not revealed, and all data were automatically stored in the US device memory. The demographic data of all patients were also recorded. Standard descriptive statistics of demographic data and SE measurements were also performed using gender distribution with standard deviations. Mean elastographic strain ratio values were calculated for gender groups (as males and females) and for the combined group.

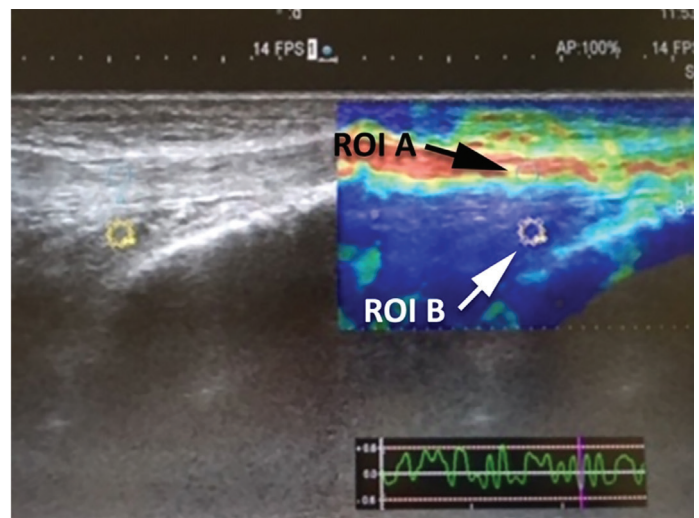


Figure 2. Location of the two ROIs 1 cm proximal from patellar insertion area. Selected quadriceps tendon area (ROI A) and the prefemoral fat pad area (ROI B). Strain elastography ratios (B/A) were calculated by the elastography software of the ultrasonography device

Parameter	Control group		Study group		"p"
	Value	Min-max	Value	Min-max	
Age	54.72±13.84	26-74	58.18±14.41	24-85	0.310 [¶]
Height	163.22±10	147-190	166.68±9.4	150-187	0.140 [¶]
Weight	71±10.67	50-92	83.8±98.72	50-115	0.470 [¶]
BMI	26.72±3.32	18.55±33.26	30.16±3.98	21.15±38.66	0.232
QT	5.81±0.93	4.3-8.3	6.55±1.77	3.6-10.4	0.030 ^{*¶}
F/Q	8.49±15.07	0.02-51.67	6.88±15.82	0.01-59.33	0.660 [¶]

Data distribution of study (chronic renal failure patients, n=40) and control groups (n=32) according to age, height, body weight, BMI: Body mass index, QT: Quadriceps tendon thickness, F/Q: Strain value ratio of prefemoral fat pad (F)/quadriceps tendon (Q)*: p<0.05; ¶: Student's t-test, *:Mann-Whitney U test

Statistical Analysis

The results of the tests were expressed as the number of observations (n), mean ± standard deviation, median and min-max values (Table 1). The results of the homogeneity (Levene's test) and normality tests (Shapiro-Wilk) were used to decide which statistical methods to apply in the comparison of the study groups. Normally distributed and with homogeneous variances groups were compared using Student's t-test (two groups). According to these test results, parametric test assumptions were not available for some variables; therefore, non-parametric comparisons of two and three independent groups were performed by Mann-Whitney U test. Categorical data were analyzed using Fischer's Exact test and chi-square test. In cases with expected frequencies of less than 25%, "Monte Carlo Simulation Method" was used for inclusion analysis. SPSS 20 (IBM Corp. Released 2011. IBM SPSS Statistics for Windows, Version 20.0. Armonk, NY: IBM Corp.) software was used for the calculations.

Results

In the study group, 40 randomly allocated patients [24 male (70.6%) and 16 female [42.1%], mean [± standard deviation (SD)] age: 58.18±14.41 years (range: 24-75)] with chronic renal failure undergoing a dialysis program 3 days a week were included. The mean quadriceps tendon thickness values in the chronic renal failure group were (mean ± SD: 6.55±1.77 mm, range: 3.6-10.4 mm) significantly higher than those in the control group (mean ± SD: 5.81±0.93 mm, range: 4.3-8.3 mm) (p=0.030; Student's t-test, Table 1). Comparison of the mean elasticity scores between the study group (mean ± SD: 6.88±15.82) and the control group (mean ± SD: 8.49±15.07) showed no statistically significant difference (p=0.660; Mann-Whitney U test, Table 1).

Discussion

In this study, the mean elasticity scores from the SE evaluation of patients with chronic renal failure revealed no statistically significant difference compared with the control group (p=0.660). However, compared with healthy controls, mean quadriceps tendon thickness values were found to be significantly higher in patients with chronic renal failure (p=0.030).

Quadriceps tendon rupture is a relatively uncommon injury predominantly affecting middle-aged males^(1,14). The inherent structural and biomechanical properties of the extensor mechanism allow the quadriceps tendon to sustain loads up to 17.5 times body weight without failure; however, the low-energy pattern of injury reported in the majority of cases suggests a weakened area of tendon tissue⁽¹⁾. Age-related changes in the tendon tissue, such as fatty and myxoid degeneration, sclerosis, and decreased tendon thickness with muscular atrophy, may result in changes in the type and cross-linking of collagen fibers of the quadriceps tendon, predisposing to rupture⁽¹⁾. In addition, several systemic/metabolic diseases have been shown to affect the quadriceps tendon and muscle, including renal failure, diabetes, hyperparathyroidism, rheumatoid arthritis, systemic lupus erythematosus, gout, osteomalacia, infection, steroid use, and obesity^(1,4,15-17). These metabolic diseases weaken the mechanical strength of the tendons by damaging the vascular supply and/or altering their microstructural properties. In patients with chronic renal failure, long periods of hemodialysis and uremia affect the maturation of collagen and cause quadricep muscle

Atrophy resulting in significant weakening of the tendon. Konrath et al.⁽¹⁸⁾, retrospectively reviewed 51 quadriceps tendon ruptures in 39 patients with bilateral and unilateral quadriceps tendon ruptures and reported a significant

correlation between bilateral simultaneous rupture and systemic disease. Although spontaneous rupture of the quadriceps tendon tends to occur in older patients with degenerative changes or those with systemic/metabolic diseases, there may also be a genetic link implicated in bilateral quadriceps tendon rupture with the *COL5A1* gene, which encodes the protein for type-V collagen and has been previously shown to be associated with Achilles tendon and anterior cruciate ligament ruptures⁽¹⁹⁾. The most common location of spontaneous rupture of the quadriceps tendon occurs at 1–2 cm proximal to the patella, which corresponds to the most hypovascular part of the tendon⁽²⁰⁾. Therefore, we preferred to evaluate this area for SE measurements.

Studies concerning elastographic evaluation of the quadriceps tendon in patients with chronic renal failure are extremely limited. Teber et al.⁽²⁾ analyzed SE findings of the quadriceps tendon in 53 patients with chronic renal failure. The authors reported that in patients with chronic renal failure, quadriceps tendons were thinner and had lower elasticity scores than controls. However, our results showed no significant difference in elasticity scores but significantly higher tendon thickness in patients with chronic renal failure.

Study Limitations

This study also has some limitations. The relatively limited number of patients in the study group may have influenced the results. Magnetic resonance correlation with SE findings may be considered; however, a reference standard for comparative evaluation (with SE) of the quadriceps tendon is lacking. Equipment variations and operator experience may also impact the results. In our study, all measurements were performed by the same blinded radiologist (experienced 4 years in SE) using the same equipment. Histopathological validation of tendinous pathology may be considered as another limitation of this study.

Conclusion

In musculoskeletal imaging, RTS provides a completely new perspective and provides further information about soft tissue quality and characteristics by assessing tissue elasticity, thus extending the diagnostic capabilities of B-mode ultrasound. Long-term randomized controlled studies with larger patient numbers are necessary to evaluate the value and efficacy of this new technique.

Ethics

Ethics Committee Approval: This study was approved by the Clinical Research Ethical Committee of Bařkent University (ref no: KA-19/21).

Informed Consent: A written informed consent form was obtained from all patients.

Authorship Contributions

Surgical and Medical Practices: E.A., S.K.M., A.G.T.K., Concept: E.A., S.K.M., A.G.T.K., Design: E.A., S.K.M., Data Collection or Processing: E.A., S.K.M., A.G.T.K., M.A.T., M.A., Analysis or Interpretation: E.A., M.A.T., Literature Search: E.A., M.A., Writing: E.A., S.K.M.

Conflict of Interest: No conflict of interest was declared by the authors.

Financial Disclosure: The authors declared that this study received no financial support.

References

1. Cancienne JM, Gwathmey FW, Diduch DR. Quadriceps and patellar tendon disruption. In Scott WN ed. *Insall & Scott Surgery of the Knee*. 6th ed. Philadelphia, PA: Elsevier; 2018:967-84.
2. Teber MA, Ođur T, Bozkurt A, et al. Real-time sonoelastography of the quadriceps tendon in patients undergoing chronic hemodialysis. *J Ultrasound Med*. 2015;34:671-7.
3. Anderson WE 3rd, Habermann ET. Spontaneous bilateral quadriceps tendon rupture in a patient on hemodialysis. *Orthop Rev*. 1988;17:411-4.
4. Harcke HT, Grissom LE, Finkelstein MS. Evaluation of the musculoskeletal system with sonography. *AJR Am J Roentgenol*. 1988;150:1253-61.
5. Shah MK. Simultaneous bilateral quadriceps tendon rupture in renal patients. *Clin Nephrol*. 2002;58:118-21.
6. Kazımođlu C, Yađdı S, Karapınar H, Sener M. Kronik renal yetmezlikli bir hastada femur boyun kiriđi ve iki taraflı kuadriseps tendon kopması [Bilateral quadriceps tendon rupture and coexistent femoral neck fracture in a patient with chronic renal failure]. *Acta Orthop Traumatol Turc*. 2007;41:393-6. Turkish.
7. Raatikainen T, Karpakka J, Orava S. Repair of partial quadriceps tendon rupture. Observations in 28 cases. *Acta Orthop Scand*. 1994;65:154-6.
8. Stoller DW, Li AE, Anderson LJ, Cannon WD. The Knee. In: Stoller DW ed. *Magnetic Resonance Imaging in Orthopaedics and Sports Medicine*, Lipincott Williams&Wilkins, 3rd ed. Baltimore, MD, Philadelphia, PA: 2007:305-731.
9. Teefey SA, Middleton WD, Yamaguchi K. Shoulder sonography. State of the art. *Radiol Clin North Am*. 1999;37:767-85.
10. Itoh A, Ueno E, Tohno E, et al. Breast disease: clinical application of US elastography for diagnosis. *Radiology*. 2006;239:341-50.
11. Friedrich-Rust M, Wunder K, Kriener S, et al. Liver fibrosis in viral hepatitis: noninvasive assessment with acoustic radiation force impulse imaging versus transient elastography. *Radiology*. 2009;252:595-604.
12. Lee SU, Joo SY, Kim SK, Lee SH, Park SR, Jeong C. Real-time sonoelastography in the diagnosis of rotator cuff tendinopathy. *J Shoulder Elbow Surg*. 2016;25:723-9.

13. Dickson DM, Fawole HO, Newcombe L, Smith SL, Hendry GJ. Reliability of ultrasound strain elastography in the assessment of the quadriceps and patellar tendon in healthy adults. *Ultrasound*. 2019;27:252-61.
14. Clayton RA, Court-Brown CM. The epidemiology of musculoskeletal tendinous and ligamentous injuries. *Injury*. 2008;39:1338-44.
15. Liow RY, Tavares S. Bilateral rupture of the quadriceps tendon associated with anabolic steroids. *Br J Sports Med*. 1995;29:77-9.
16. Miles JW, Grana WA, Egle D, Min KW, Chitwood J. The effect of anabolic steroids on the biomechanical and histological properties of rat tendon. *J Bone Joint Surg Am*. 1992;74:411-22.
17. Shah MK. Simultaneous bilateral rupture of quadriceps tendons: analysis of risk factors and associations. *South Med J*. 2002;95:860-6.
18. Konrath GA, Chen D, Lock T, et al. Outcomes following repair of quadriceps tendon ruptures. *J Orthop Trauma*. 1998;12:273-9.
19. Galasso O, Iaccino E, Gallelli L, et al. Collagen type V polymorphism in spontaneous quadriceps tendon ruptures. *Orthopedics*. 2012;35:e580-4.
20. Yepes H, Tang M, Morris SF, Stanish WD. Relationship between hypovascular zones and patterns of ruptures of the quadriceps tendon. *J Bone Joint Surg Am*. 2008;90:2135-41.