

Morgagni Hernia in a Patient with Seizures

Nöbetleri Olan Bir Hastada Morgagni Hernisi

İlçay Keskinel¹, Müzeyyen Eryılmaz²

¹Okan University Faculty of Medicine, Department of Chest Diseases, İstanbul, Türkiye

²University of Health Sciences Türkiye, Fatih Sultan Mehmet Training and Research Hospital, Clinic of Internal Medicine, İstanbul, Türkiye

Cite as: Keskinel İ, Eryılmaz M. Morgagni hernia in a patient with seizures. Anatol J Gen Med Res. 2026;36(1):1-2

Keywords: Diaphragmatic hernia, epilepsy, morgagni hernia, seizure

Anahtar Kelimeler: Diyafram hernisi, epilepsi, morgagni hernisi, nöbet

To the Editor,

Morgagni diaphragmatic hernia (MDH) is characterized by an orifice in the diaphragm, usually on the right side, that allows herniation of abdominal contents into the thorax⁽¹⁾. MDH accounts for approximately 3% of all diaphragmatic hernias^(2,3). It typically manifests later in life, either due to respiratory or gastrointestinal issues or as an incidental finding in asymptomatic adults. Diagnosis is confirmed through chest X-rays and computed tomography (CT) scans.

MDH is a rare clinical entity in adults, with no well-documented prevalence or natural history⁽⁴⁾. Predisposing factors such as trauma, obesity, and increased intraabdominal pressure due to chronic cough or constipation can contribute to herniation. However, only 50% of MDH cases present with predisposing factors.

We report a case of a 39-year-old female patient with MDH and epileptic seizures. She presented with worsening dyspnea over several years, exacerbated when lying supine. Her medical history included epilepsy for 17 years, type II diabetes, hypertension, and vitamin B12 deficiency. A heavy smoker for 20 years, she was on levetiracetam for epilepsy and metformin for diabetes. Physical examination revealed decreased breath sounds in the lower right hemithorax. A chest X-ray showed a homogeneous opacity in the right

lower lung zone, and a CT scan confirmed the diagnosis of MDH (Figure 1). Pulmonary function tests indicated a mild restrictive ventilatory defect.

The patient underwent successful open surgery for hernia repair (Figure 2), and her postoperative course was uneventful. Follow-up chest X-rays confirmed a normal diaphragm and pulmonary structures (Figure 3). In a one-year follow-up after surgery, the patient reported significant improvement in dyspnea and had no epileptic seizures.

MDH was first described by Giovanni Battista Morgagni in 1761⁽¹⁾. Among congenital diaphragmatic hernias, Bochdalek hernias are the most common, accounting for about 90% of cases⁽⁵⁾. MDH, which is less common, is predominantly found in females and obese individuals, and is usually located on the right side⁽²⁾. CT scans with contrast media are the preferred diagnostic tool for MDH, as they are more sensitive than standard X-rays⁽³⁾.

There are few case reports linking MDH to neurological or respiratory symptoms. Pattnaik et al.⁽³⁾ described a female patient with MDH and asthma, whose respiratory symptoms improved after hernia repair. Zisa et al.⁽⁴⁾ reported a male patient with both MDH and seizures, suggesting that intra-abdominal pressure related to seizures may contribute to herniation. Acampora et al.⁽⁵⁾ also reported a case where



Address for Correspondence/Yazışma Adresi: Lec. İlçay Keskinel MD, Okan University Faculty of Medicine, Department of Chest Diseases, İstanbul, Türkiye
E-mail: ilckaykeskinel@gmail.com
ORCID ID: orcid.org/0000-0003-2683-5076

Received/Geliş tarihi: 17.12.2024

Accepted/Kabul tarihi: 17.01.2025

Epub: 29.05.2025

Published date/Yayınlanma tarihi: 30.04.2026



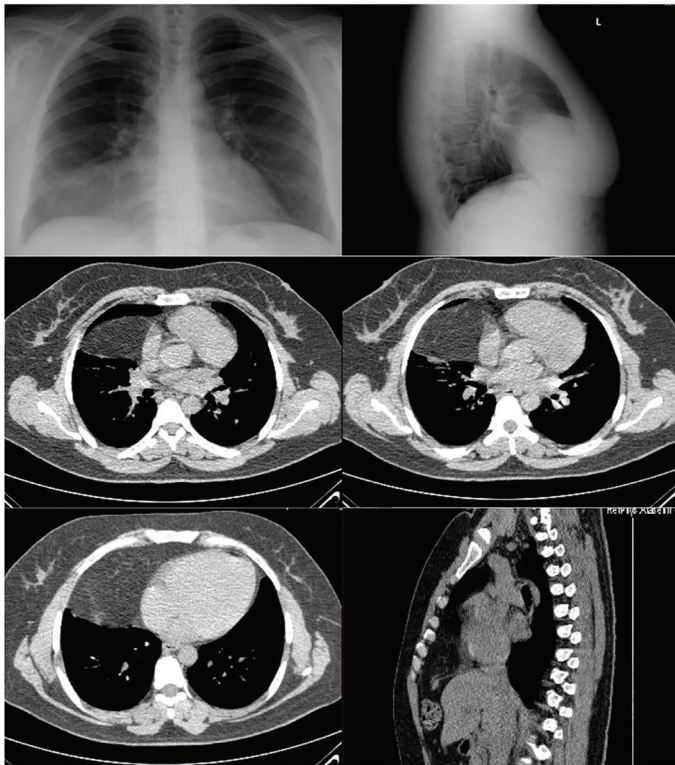


Figure 1. Preoperative posteroanterior, lateral chest X-ray and thorax CT images of the patient
CT: Computed tomography

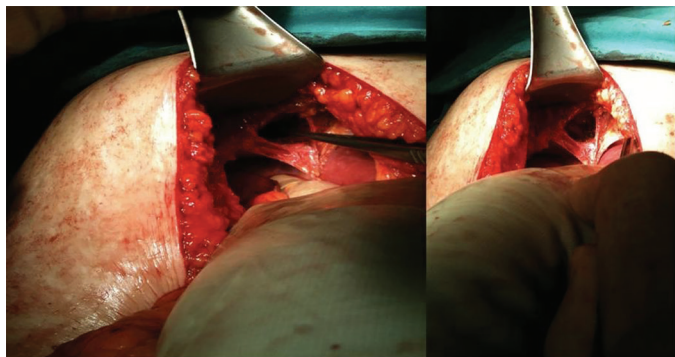


Figure 2. Intraoperative view of the diaphragmatic defect due to Morgagni hernia

recurrent convulsive syncope resolved after MDH repair. In line with these findings, our patient's seizures subsided after surgical intervention, suggesting a potential relationship between MDH and seizure activity.

This case contributes to the limited literature on MDH and its possible association with seizures. Surgical repair of MDH in such cases may help alleviate neurological symptoms, and further studies are warranted to investigate this relationship.

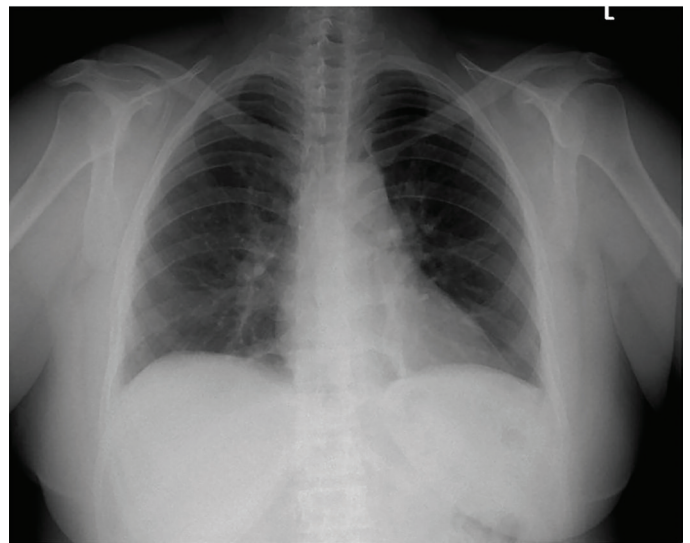


Figure 3. Postoperative posteroanterior chest X-ray of the patient

Footnotes

Authorship Contributions

Surgical and Medical Practices: İ.K., Concept: İ.K., M.E., Design: İ.K., Data Collection or Processing: İ.K., M.E., Analysis or Interpretation: İ.K., M.E., Literature Search: İ.K., M.E., Writing: İ.K.

Conflict of Interest: No conflict of interest was declared by the authors.

Financial Disclosure: The authors declared that this study received no financial support.

References

1. Abraham V, Myla Y, Verghese S, Chandran BS. Morgagni-larrey hernia- a review of 20 cases. *Indian J Surg.* 2012;74:391-5.
2. Sarıçık B, Yıldız İ, Koca YS. Incarcerated giant Morgagni hernia: case report. *Bozok Med J* 2018;8:158-61.
3. Pattnaik MK, Sahoo SP, Panigrahy SK, Nayak KB. Morgagni hernia: a rare case report and review of literature. *Lung India.* 2016;33:427-9.
4. Zisa M, Pulvirenti E, Toro A, Mannino M, Reale G, Di Carlo I. Seizure attack and Morgagni diaphragmatic hernia: incidental diagnosis or direct correlation? *Updates Surg.* 2011;63:55-8.
5. Acampora R, Marte G, Scala R, Lieto M, Maida P, Mazzaferro MP. Recurrent convulsive syncope misdiagnosed as seizures due to a diaphragmatic hernia. *Neurol Sci.* 2021;42:4727-9.